

## PRACTICE



## 10-MINUTE CONSULTATION

## Progressive elbow pain

Alexis Descatha *occupational/emergency practitioner, professor*<sup>1 2</sup>, Thomas Despréaux *chief resident*<sup>1 2</sup>, Ryan P Calfee *hand surgeon, associate professor*<sup>3</sup>, Bradley Evanoff *occupational medicine physician, professor*<sup>4</sup>, Olivier Saint-Lary *general practitioner, senior lecturer*<sup>5 6</sup>

<sup>1</sup>AP-HP, Occupational Health Unit/EMS (Samu92), University hospital of Poincaré site, France; <sup>2</sup>Versailles St-Quentin University UVSQ Inserm, UMS 011 - UMR-S 1168, France; <sup>3</sup>Department of Orthopedic Surgery, Washington University School of Medicine, St Louis, Missouri, USA; <sup>4</sup>Institute of Clinical and Translational Sciences/ Division of General Medical Sciences, Washington University School of Medicine, St Louis, Missouri, USA; <sup>5</sup>Université Versailles Saint-Quentin en Yvelines, Faculty of Health Sciences Simone Veil, Department of Family Medicine, 78180 Montigny le Bretonneux, France; <sup>6</sup>Université Paris-Saclay, Univ Paris-Sud, UVSQ, CESP, INSERM (U1018), Team 1: "Health services research," 94800 Villejuif, France.

A 50 year old supermarket cashier complains of progressive elbow pain for the past two weeks. It is hard for her to scan heavy items at work and to lift saucepans at home.

**What you should cover**

Lateral elbow pain is common (population prevalence 1-3%).<sup>1</sup> It is usually assessed and managed in primary care, and the incidence of lateral elbow pain in general practice is 4-7/1000 people a year.<sup>2</sup> Interrupted sleep, inability to use the hand, and psychological ill health (anxiety or depression) are associated with problems functioning at home or work.

Ask questions to explore which structures in the elbow are likely to be affected.

- Pain on specific movement may suggest tendinitis, which may follow increased levels of activity and recur:
  - Those with lateral epicondylitis (tennis elbow) characteristically have pain on gripping or lifting palm-down, typically with activities such as tennis, kayaking, construction work, and assembly line work (strong evidence for such association in systematic reviews)<sup>3</sup>
  - Medial epicondylitis (golfer's elbow) is typically aggravated by activities involving grip and wrist or elbow flexion such as rock climbing, turning and screwing, and using tools forcefully (with a lower evidence, however)<sup>1</sup>
  - Other forms of tendinitis, such as rotator cuff, may cause referred pain around the elbow.<sup>3</sup>
- Loss of flexion and extension with end-range pain is suggestive of osteoarthritis.

- Numbness or muscle weakness may indicate a neuropathy, perhaps affecting the radial nerve, or radiculopathy C6-C8.
- Be alert to the possibility of inflammatory or septic arthritis.
- Consider whether there is relevant old or new trauma.

**Examination**

Expose the patient's arms. Look for deformity, swelling, or soft tissue damage consistent with an old or new traumatic injury. Ask the patient to point to the area of maximal pain, indicate radiation, and demonstrate movements that provoke the pain.

Palpate the elbow. Figure 1⇓ depicts the areas of maximal tenderness for lateral and medial epicondylitis, osteoarthritis, and radial tunnel syndrome.

Perform special tests for tendinopathy. For lateral tendinopathy, ask the patient to dorsiflex the wrist against resistance with the elbow flexed 90°—extending the elbow increases pain further. In the context of medial pain also check for associated ulnar entrapment at the elbow with a positive combined pressure and flexion test.<sup>3</sup>

Consider examination for pathology of the shoulder, rotator cuff, and neck if the diagnosis is not clear.

**What you should do**

Lateral epicondylitis (tennis elbow) is the most common cause of persistent elbow pain, responsible for two thirds of cases presenting in general practice.<sup>4</sup> It will improve spontaneously in around 80-90% of people over 1-2 years.<sup>5</sup> Analgesia, work

Correspondence to: O Saint-Lary olivier.saint-lary@uvsq.fr

This is part of a series of occasional articles on common problems in primary care. The *BMJ* welcomes contributions from GPs.

**What you need to know**

- Elbow pain on specific movements suggests tendonitis, and tennis elbow is the most common
- Examine the shoulder if the diagnosis is not clear
- Optimal treatment of tennis elbow is unclear, but pain control, work modification, physiotherapy, and orthotics may help to reduce symptoms. Corticosteroid injections provide better pain relief at six weeks, but by six months the symptoms in this group are no better and sometimes worse

modification, and physiotherapy may help to manage symptoms but are not known to alter the long term prognosis.

Systematic reviews and meta-analysis have evaluated treatment of tennis elbow, but the low quality of included studies and the lack of long term follow-up limit any conclusions. However, accepted practice is:

- Offer short term regular paracetamol. Non-steroidal anti-inflammatory drugs (NSAIDs) may help but should be reduced as soon as possible. A recent Cochrane review concluded that NSAIDs (oral and topical) are ineffective in this condition in the long term while increasing side effects (abdominal pain).<sup>6</sup>
- Advise a short cessation of aggravating sports and manual work while maintaining activity. Physiotherapy focuses on maintaining motion and strengthening exercises (fig 2⇓), possibly with the aid of wrist cock-up brace or epicondylar counterforce (elbow) brace.
- In the past corticosteroid injections were offered. For lateral epicondylitis they provide temporary (six weeks) pain relief which may be superior to that provided by NSAIDs and physical therapies.<sup>2</sup> By six months, however, patients treated with steroid injection report either the same or more symptoms than those who did not receive an injection.<sup>2</sup>
- Suggest that the patient tries to reduce instances of forceful grip, wrist extension, and elbow flexion, and duration of such movement, in work and in sport (recommended by the American College of Occupational and Environmental Medicine (ACOEM) practice guidelines with an “insufficient level of evidence” based on observational studies).<sup>7</sup> This may be supported by instructions for the employer, such as to mix work patterns, increase the number of rest breaks, and, if feasible, to change the way to manipulate objects with forceful gripping and awkward wrist posture.
- Advise patient to return in case of increasing pain, difficulty in sleeping or in functioning well at home or work, or

unusual persistence (>6-12 months). In such cases, re-examine the patient and possibly refer to a specialist from rehabilitation or surgery (immediately in the case of initial severity).<sup>8</sup>

- Reassure the patient that it is unlikely to result in long term disability and does not cause arthritis.
- Imaging and referral should be performed in case of unusual pain location or severity, or associated symptoms, and when needed to rule out an alternative diagnosis (bone and joint disorders, nerve entrapment).

**Contributors:** All authors helped to initiate the work. AD wrote the first draft of the manuscript, and all authors edited the manuscript and validated the final version. OSL is guarantor for the article.

**Competing interests:** We have read and understood BMJ policy on declaration of interests and have no relevant interests to declare.

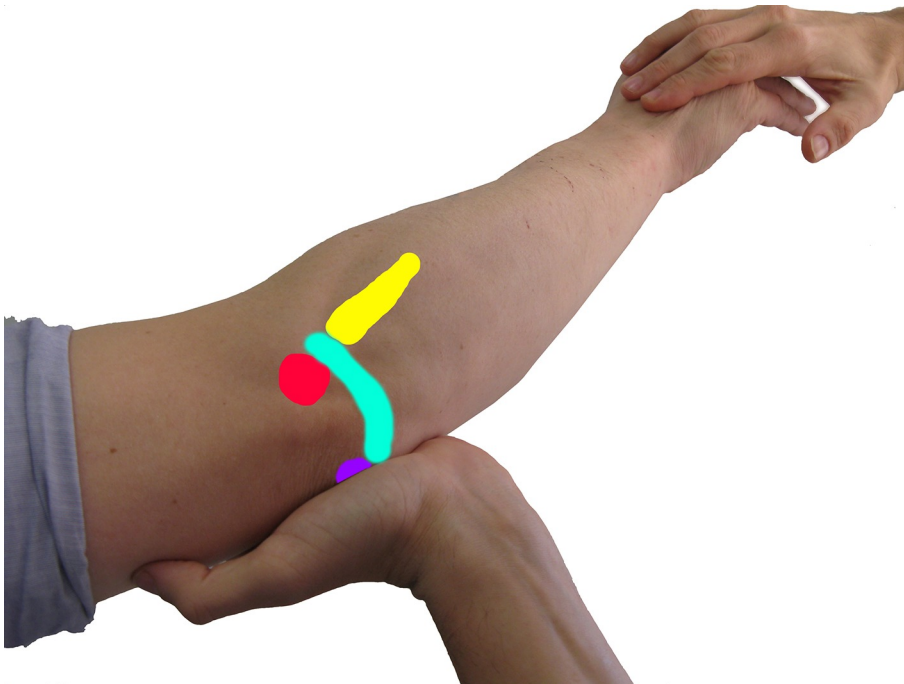
**Provenance and peer review:** Not commissioned; externally peer reviewed.

- 1 Shiri R, Viikari-Juntura E. Lateral and medial epicondylitis: role of occupational factors. *Best Pract Res Clin Rheumatol* 2011;25:43-57.pmid:21663849.
- 2 Bisset L, Coombes B, Vicenzino B. Tennis elbow. *BMJ Clin Evid* 2011;2011:1117.pmid:21708051.
- 3 Kane SF, Lynch JH, Taylor JC. Evaluation of elbow pain in adults. *Am Fam Physician* 2014;89:649-57.pmid:24784124.
- 4 Hamilton PG. The prevalence of humeral epicondylitis: a survey in general practice. *J R Coll Gen Pract* 1986;36:464-5.pmid:3440991.
- 5 Bisset L, Paungmali A, Vicenzino B, Beller E. A systematic review and meta-analysis of clinical trials on physical interventions for lateral epicondylalgia. *Br J Sports Med* 2005;39:411-22, discussion 411-22.pmid:15976161.
- 6 Pattanittum P, Turner T, Green S, Buchbinder R. Non-steroidal anti-inflammatory drugs (NSAIDs) for treating lateral elbow pain in adults. *Cochrane Database Syst Rev* 2013;5:CD003686.pmid:23728646.
- 7 Hegmann KT, Hoffman HE, Belcourt RM, et al. American College of Occupational and Environmental Medicine. ACOEM practice guidelines: elbow disorders. *J Occup Environ Med* 2013;55:1365-74.pmid:23963225.
- 8 Tosti R, Jennings J, Sowards JM. Lateral epicondylitis of the elbow. *Am J Med* 2013;126:357.e1-6.pmid:23398951.

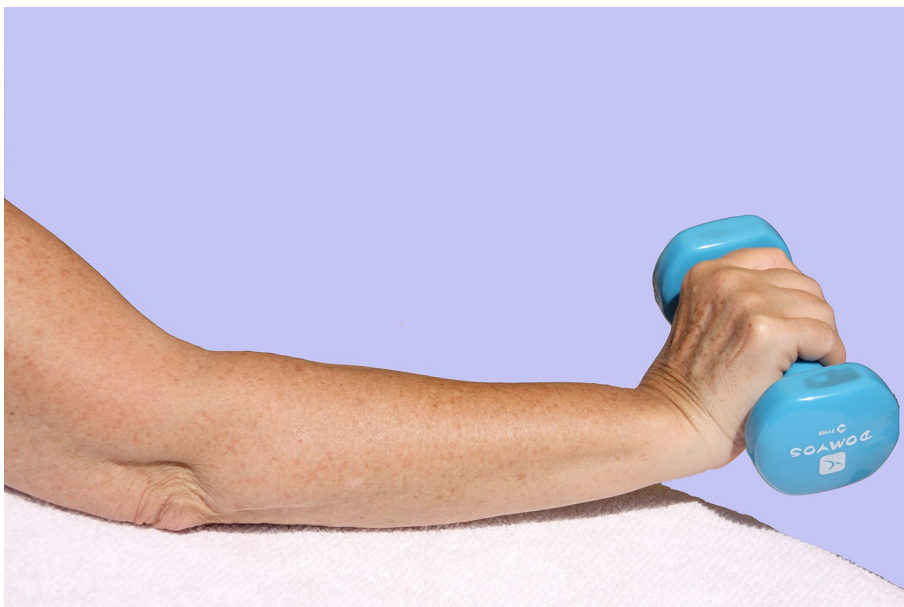**Accepted:** 11 02 2016

Published by the BMJ Publishing Group Limited. For permission to use (where not already granted under a licence) please go to <http://group.bmj.com/group/rights-licensing/permissions>

## Figures



**Fig 1** Location of pain at different sites of the elbow (upper postero-lateral view, during the provocative manoeuvre of lateral epicondylitis, applying resistance against wrist dorsiflexion). Red area = lateral epicondylitis, purple area = medial epicondylitis (partial), yellow area = radial tunnel nerve entrapment, blue area = joint disorders.



**Fig 2** Strengthening exercises. They are based on resisting wrist extension (arm resting on a table with the elbow extended), such as by slowly lowering and raising a 2 lb (0.9 kg) weight held palm-down (or by using a stretch band) for three sets of 10-15 repetitions daily for about 6-12 weeks. A wrist cock-up brace or epicondylar counterforce brace (elbow brace) can be used based on patient preference. Counterforce bracing over the wrist extensor muscle bellies distributes forces from the forearm extensors away from their origin.